



# Surgical Correction of Anal Atresia in a 4-Day-Old Brown Swiss Calf

Rodolfo Olivera-Calderon<sup>1</sup>, Edgar Meza-Miguel<sup>2</sup>, Jordan Ninahuanca<sup>1\*</sup>, Ide Unchupaico Payano<sup>1</sup>, Edgar García-Olarte<sup>1</sup>, Carolina Miranda-Torpoco<sup>3</sup>, Wilhelm Guerra Condor<sup>2</sup>, Williams Olivera-Acuña<sup>2</sup>, and Vicky Sarapura<sup>3</sup>

<sup>1</sup>Facultad de Zootecnia, Universidad Nacional del Centro del Perú, Huancayo, box 12006, Junín, Perú

<sup>2</sup>Facultad de Ciencias de la Salud, Universidad Peruana los Andes, box 12002, Junín, Perú

<sup>3</sup>Facultad de Ingeniería, Universidad Peruana los Andes, box 12002, Junín, Perú

\*Corresponding author's Email: [jninhuanca@uncp.edu.pe](mailto:jninhuanca@uncp.edu.pe)

## ABSTRACT

A 4-day-old Brown Swiss calf was presented to a veterinary clinic in Huancayo, Peru, with congenital anal atresia. The condition was characterized by an absence of defecation, progressive abdominal distension, and a blind rectal pouch confirmed radiographically. Clinical examination revealed no anal opening, moderate tympany, and normal neurological function. Surgical correction was conducted under pre-anesthetic sedation using xylazine (0.2 mg/kg IM) and sacrococcygeal epidural anesthesia with lidocaine (0.5 mL/kg). A 12-cm vertical incision in the intertubercular ischiatic region exposed the distended rectal pouch, allowing for an end-to-cutaneous anastomosis with polyglactin 910 (Vicryl® 2-0). Subsequently, a 2-3 cm distal rectal incision was created to form a neoanus. The mucosal edges were sutured to the skin margins with interrupted simple stitches (Vicryl® 3-0), a technique aimed at preventing stenosis and maintaining a neoanal diameter of approximately 1.5-2 cm. Postoperative management included prophylactic penicillin. Within three hours of surgery, the calf passed impacted meconium, indicating the functional patency of the neoanus. Although the prognosis was favorable, the patient was closely monitored for five days to detect any signs of stricture or infection. This case illustrated the effectiveness of early surgical intervention in reestablishing gastrointestinal continuity in congenital anal atresia.

**Keywords:** Anal agenesis, Clinical significance, Postoperative outcome, Surgical technique

## INTRODUCTION

Congenital anal atresia (atresia ani or anal agenesis) arises from abnormal embryological development of the caudal digestive tract. During normal organogenesis, the cloacal membrane (a transient embryonic structure that contributes to the formation of both the anal canal and urogenital tracts) undergoes perforation between the fifth and seventh weeks of gestation to establish the definitive anal opening. In individuals with anal atresia, incomplete perforation or persistence of this membrane leads to complete obstruction of the anal orifice, a hallmark of the condition (Ford et al., 2022; Su et al., 2024). Classified among posterior digestive tract anomalies, anal atresia involves disruption in the formation of the proctodeum between the fourth and seventh weeks of gestation in cattle (Su et al., 2024). Although its reported incidence is low (0.02-0.05% in calves), this anomaly is a significant contributor to neonatal mortality in livestock, particularly in genetically predisposed breeds, such as the Brown Swiss (Kancherla et al., 2023).

In cattle, anal atresia typically presents with acute intestinal obstruction, manifested by abdominal distension, tenesmus, and failure to pass meconium. Early surgical intervention is crucial to prevent life-threatening complications, including intestinal perforation and sepsis (Patel et al., 2024). This case report may represent one of the first documented instances of congenital anal atresia in Peruvian cattle. Worldwide, only a few similar cases have been reported recently, including those in Brazil by Fernandes et al. (2021) and Teixeira and de Araujo (2022) in Bangladesh by Rahman and Alam (2022), and in India by Patel et al. (2024), highlighting both the rarity and clinical significance of the condition. Hence, the objective of this study was to describe the successful surgical management of congenital anal atresia in a Brown Swiss calf.

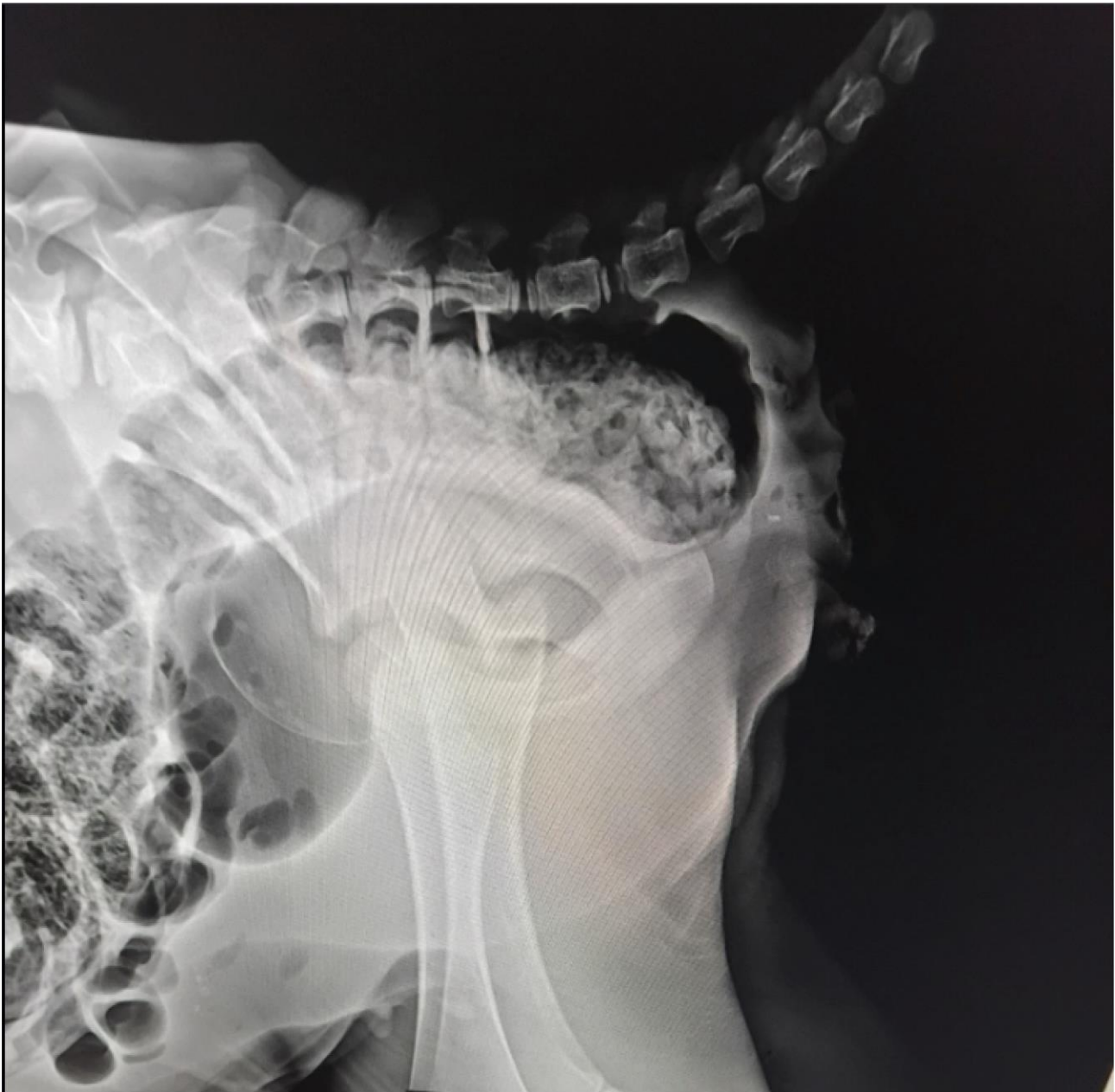**CASE REPORT**  
Received: January 03, 2025  
Revised: February 06, 2025  
Accepted: March 02, 2025  
Published: March 31, 2025

## CASE PRESENTATION

The animal owner provided informed consent for the surgical procedure and submitted a certificate of animal welfare ethics (CARTA N° 001-GRJ-DRA-AAC-PERÚ-2025), which endorses compliance with health and animal welfare standards.

A 4-day-old Brown Swiss calf was brought to the Veterinaria Paulo Social clinic in Huancayo, Peru, due to an absence of defecation since birth. According to the owner, the calf had not passed meconium or feces, resulting in progressive abdominal distension. Macroscopic examination of the perineal region revealed no anal opening and no evidence of rectovaginal fistula or other urogenital anomalies. The clinical assessment confirmed moderate tympany but no systemic signs of sepsis. Both consciousness and response to stimuli were normal, ruling out any neurological involvement.

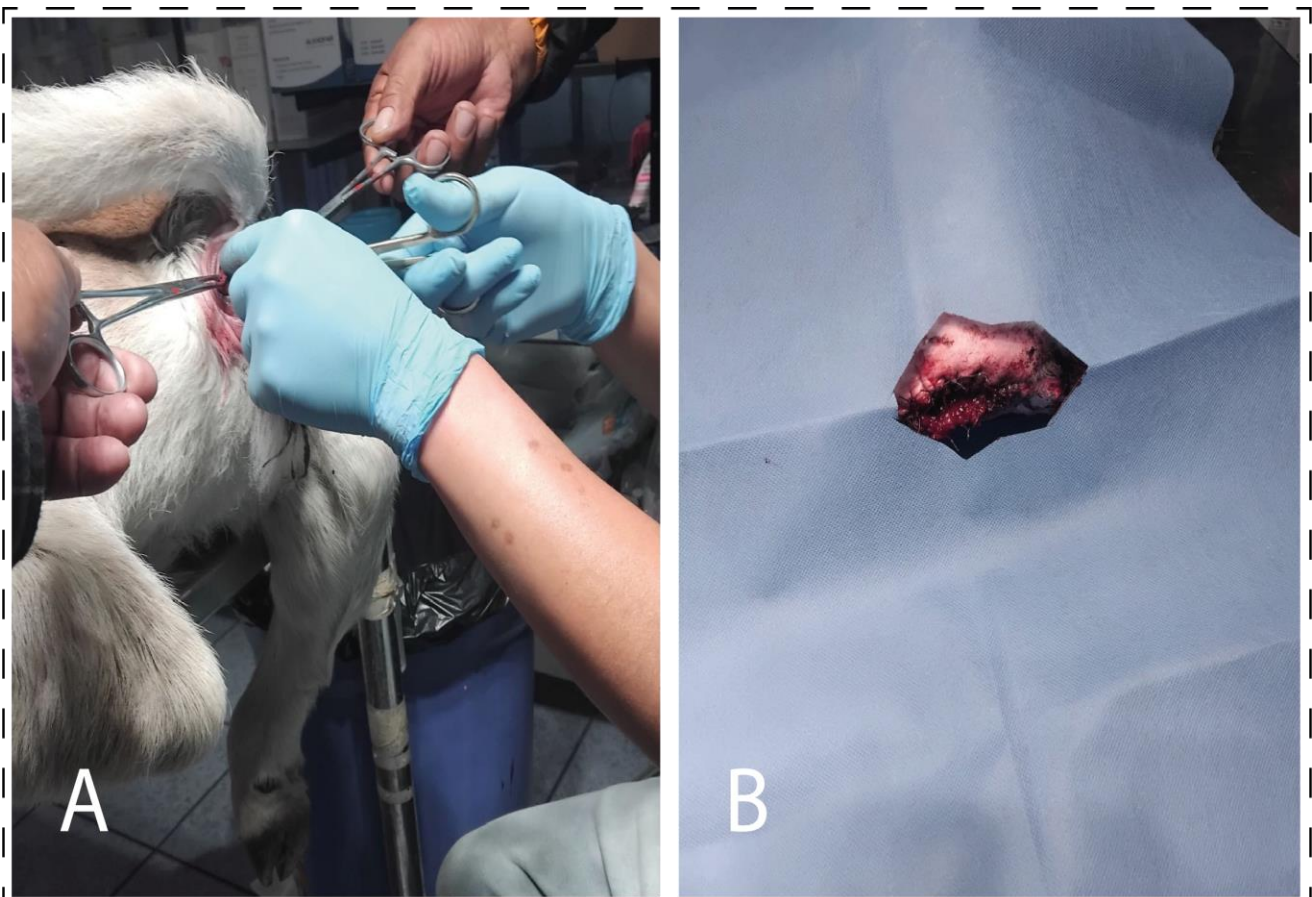
Lateral radiographs indicated a blind-ended rectal pouch located approximately 2 cm from the perineal skin, with no external communication (Figure 1). Marked distension of the rectum and colon was noted, characterized by fecal and gaseous accumulation proximal to the obstruction. Dilatation of the distal intestinal loops confirmed a complete functional obstruction. No major bony malformations or additional spinal or abdominal abnormalities were identified.



**Figure 1.** The caudal end of the rectum in a 4-day-old Brown Swiss calf

Prior to surgery, pre-anesthetic sedation (Xylazine, Xilagal®, 0.2 mg/kg IM) was administered, followed by sacrococcygeal epidural anesthesia (Lidocaine®, 0.5 mL/kg; [Doherty et al., 2007](#); [Alexander et al., 2022](#)). A 12 cm vertical incision was made in the intertubercular ischiatic region corresponding to the terminal rectal pathway. Blunt dissection of the subcutaneous and fascial layers revealed pelvic floor structures, including a distended blind rectal pouch filled with fecal matter (Figure 2A). The distal rectal segment showed viable tissue (pink coloration, intact blood supply), with no signs of necrosis or previous trauma. Babcock forceps were used to secure and exteriorize the rectum. An end-to-cutaneous anastomosis was performed using a simple continuous suture pattern with absorbable polyglactin 910 (Vicryl® 2-0), approximating the rectal seromuscular layer to the perineal dermis. A 2-3 cm longitudinal incision was made in the distal rectal wall to create a functional opening. The mucosal edges were sutured to the skin margin with interrupted simple stitches (Vicryl® 3-0) (Figure 2B) to prevent stenosis and maintain a neoanus diameter of 1.5-2 cm. Patency was confirmed by digital palpation and direct visualization of healthy rectal mucosa. Meticulous hemostasis was maintained, and the surgical site was closed in layers to preserve anatomic and functional integrity.

Postoperatively, a multimodal protocol was implemented to prevent infection, control pain, and reduce inflammation. Procaine penicillin G (Pen®, 5 mL IM every 24 hours for 2 days) was given for broad-spectrum antibiotic prophylaxis, aligning with guidelines for gastrointestinal surgery in ruminants ([Berge et al., 2005](#)). Anti-inflammatory and analgesic therapy comprised Flunixin Meglumine (1.1 mg/kg IM every 24 hours for 48 hours), a COX-2-inhibiting NSAID, in combination with butorphanol (0.1 mg/kg IM every 8 hours for 2 days) for short-acting opioid analgesia ([Alexander et al., 2022](#)). The calf demonstrated early resumption of feeding and displayed only mild, localized discomfort, with no signs of acute pain (Figure 3A). Three hours post-surgery, it passed the impacted meconium, confirming the functionality of the newly created anus (Figure 3B). An Elizabethan collar was employed to prevent the calf from licking the surgical site, which could compromise wound healing or disrupt sutures. The prognosis remains favorable, with continued monitoring for potential stenosis or infection over a 5-day follow-up period.



**Figure 2.** Surgical correction of Atresia Ani in a Brown Swiss calf. **A:** Surgical Procedure, intraoperative image showing the exteriorization and incision of the blind-ended rectal pouch. **B:** Excised Tissue, resected atretic rectal segment following dissection.



**Figure 3.** Postoperative condition of a brown Swiss calf with Atresia Ani. **A:** The Postoperative status, the Brown Swiss calf, shows normal behavior after surgery. **B:** The postoperative outcome, the Brown Swiss calf, shows the newly operated anal orifice after surgical correction.

## DISCUSSION

Congenital anal atresia, while uncommon in cattle, presents a significant clinical and etiological challenge, as demonstrated by this first documented Peruvian case involving a 4-day-old Brown Swiss calf. Embryologically, the malformation stems from incomplete perforation of the cloacal membrane between the fourth and seventh weeks of gestation, resulting in defective proctodeal development (de Blaauw et al., 2024). The clinical presentation, characterized by acute abdominal distension, tenesmus, and failure to pass meconium, aligns with classic descriptions of the condition and highlights the need for timely intervention to prevent life-threatening sequelae, such as intestinal rupture or septicemia (Herman and Teitelbaum, 2012; Iwai and Fumino, 2013; Jacobs et al., 2022).

The perineal proctoplasty in this case successfully reestablished both anatomical and functional continuity through an end-to-cutaneous anastomosis with absorbable polyglactin 910 sutures (Vicryl®). This technique, regarded as the gold standard for low-type atresias (type I), achieved immediate postoperative patency, evidenced by the evacuation of impacted meconium within three hours. This outcome aligns with findings from Brazilian herds (Fernandes et al., 2021). The absence of fistulas simplified the surgical approach and improved prognosis since fistulas frequently require additional reparative procedures and elevate the risk of fecal contamination or postoperative infection (Rogers and Jeppson, 2016). This variation suggests the influence of genetic predisposition, epigenetic factors, or environmental triggers on phenotypic expression, warranting further research.

Prophylactic measures, including procaine penicillin administration and lumbosacral epidural analgesia, were instrumental in minimizing perioperative infection and stress, aligning with evidence-based protocols for bovine gastrointestinal surgery (Yarmuch et al., 2015). Despite these precautions, long-term complications, such as stenosis (driven by excessive collagen deposition at the anastomosis site due to surgical trauma, tension, or suboptimal mucosal apposition) and partial fecal incontinence (associated with external anal sphincter or pelvic nerve damage) may appear months after surgery (Xiong et al., 2020). To mitigate these risks, pelvic floor physiotherapy (to strengthen sphincter tone), periodic digital palpation, or endoscopic evaluations during follow-up can detect early stricture formation, allowing timely interventions, such as balloon dilation or revision surgery. This case not only demonstrates the efficacy

of early surgical correction but also addresses a critical gap in regional veterinary literature as the first reported case in Peru. It underscores the importance of documenting congenital anomalies in underrepresented livestock populations to enhance the global understanding of disease prevalence, refine breed-specific management strategies, and improve prognostic accuracy.

## CONCLUSION

This case report demonstrated the effectiveness of prompt surgical correction for congenital anal atresia in calves. Timely intervention combined with precise surgical methods and preventive care successfully reestablished gastrointestinal continuity and minimized immediate postoperative complications. Long-term prognosis relies on vigilant monitoring for stenosis and adherence to breeding strategies designed to lower the incidence of congenital defects in susceptible breeds. Additionally, the study highlighted the value of recording and sharing clinical experiences in regions that are underrepresented in the literature, thereby moving toward standardized and accessible protocols for diverse livestock settings.

## DECLARATIONS

### Funding

The study received no financial assistance.

### Availability of data and materials

The data of the current case report are available upon reasonable request from the corresponding author.

### Acknowledgments

The authors would like to thank all the staff of the “Veterinaria Paulo Social” in Huancayo, Peru.

### Authors' contributions

Rodolfo Olivera-Calderon conceptualized the study and designed the research framework. Edgar Meza-Miguel performed the surgical procedures on the animal subjects. Jordan Ninahuanca developed and implemented the methodological approach for data collection and analysis. Ide Unchupaico Payano conducted postoperative monitoring and clinical assessments of the animals. Edgar Garcia-Olarte validated the experimental protocols and results to ensure scientific rigor. Carolina Miranda-Torpoco managed software-based image processing and analysis. Wilhelm Guerra Condor and Olivera-Acuña W supervised the operation and calibration of radiological equipment throughout the study. Vicky Sarapura coordinated the safe disposal and management of veterinary medical waste in compliance with biohazard regulations. All authors critically reviewed, edited, and approved the final version of the manuscript prior to submission for publication.

### Competing interests

The authors declare that there is no conflict of interest.

### Ethical considerations

The authors have checked and compiled the ethical issues, including plagiarism, consent to publish, misconduct, fabrication and/or falsification, double publication and/or presentation, and redundancy.

## REFERENCES

- Alexander RS, Canver BR, Sue KL, and Morford KL (2022). Xylazine and overdoses: Trends, concerns, and recommendations. *American Journal of Public Health*, 112(8): 1212-1216. DOI: <https://www.doi.org/10.2105/AJPH.2022.306881>
- Berge A, Lindeque P, Moore D, and Sischo W (2005). A clinical trial evaluating prophylactic and therapeutic antibiotic use on health and performance of preweaned calves. *Journal of Dairy Science*, 88(6): 2166-2177. DOI: [https://www.doi.org/10.3168/jds.S0022-0302\(05\)72892-7](https://www.doi.org/10.3168/jds.S0022-0302(05)72892-7)
- de Blaauw I, Stenström P, Yamataka A, Miyake Y, Reutter H, Midrio P, Wood R, Grano C, and Pakarinen M (2024). Anorectal malformations. *Nature Reviews Disease Primers*, 10(1): 88. DOI: <https://www.doi.org/10.1038/s41572-024-00574-2>

- Doherty T, Kattesh H, Adcock R, Welborn M, Saxton A, Morrow J, and Dailey J (2007). Effects of a concentrated lidocaine solution on the acute phase stress response to dehorning in dairy calves. *Journal of Dairy Science*, 90(9): 4232-4239. DOI: <https://www.doi.org/10.3168/jds.2007-0080>
- Fernandes MEDSL, Caldas SA, Rocha LR, Chenard MG, Freire KRF, da Silva Carvalho N, de Assunção Nogueira V, and Helayel MA (2021). Atresia ani (*Imperforated anus*) in calves: Clinical, surgical and pathological aspects. *Acta Scientiae Veterinariae*, 49(Suppl 1): 681. DOI: <https://www.doi.org/10.22456/1679-9216.112980>
- Ford K, Peppas M, Zylbersztejn A, Curry JI, and Gilbert R (2022). Birth prevalence of anorectal malformations in England and 5-year survival: A national birth cohort study. *Archives of Disease in Childhood*, 107(8): 758-766. DOI: <https://www.doi.org/10.1136/archdischild-2021-323474>
- Herman RS and Teitelbaum DH (2012). Anorectal malformations. *Clinics in Perinatology*, 39(2): 403-422. DOI: <https://www.doi.org/10.1016/j.clp.2012.04.001>
- Iwai N and Fumino S (2013). Surgical treatment of anorectal malformations. *Surgery Today*, 43: 955-962. DOI: <https://www.doi.org/10.1007/s00595-012-0435-y>
- Jacobs SE, Tijsaba L, Al-Shamaileh T, Bokova E, Russell TL, Ho CP, Varda BK, Pohl HG, Mayhew AC, and Gomez-Lobo V (2022). Fetal and newborn management of cloacal malformations. *Children*, 9(6): 888. DOI: <https://www.doi.org/10.3390/children9060888>
- Kancherla V, Sundar M, Tandaki L, Lux A, Bakker MK, Bergman JE, Bermejo-Sánchez E, Canfield MA, Dastgiri S, and Feldkamp ML (2023). Prevalence and mortality among children with anorectal malformation: A multi-country analysis. *Birth Defects Research*, 115(3): 390-404. DOI: <https://www.doi.org/10.1002/bdr2.2129>
- Patel A, Mahla J, Gamit M, Bhalodi A, and Mayani A (2024). X-ray assisted reconstructive surgical management of atresia ani et recti in gir calf (*Bos indicus*) with a rare incidence of anury. *International Journal of Veterinary Sciences and Animal Husbandry*, 9(1): 33-35. DOI: <https://www.doi.org/10.22271/veterinary.2024.v9.i1a.859>
- Rahman M and Alam M (2022). Surgical repair of atresia ani et recti by cecostomy operation in a cross-bred calf: A case report. *Veterinary Sciences: Research Reviews*, 8(2): 71-73. DOI: <https://www.doi.org/10.17582/journal.vsr/2022/8.2.71.73>
- Rogers RG and Jeppson PC (2016). Current diagnosis and management of pelvic fistulae in women. *Obstetrics Gynecology*, 128(3): 635-650. DOI: <https://www.doi.org/10.1097/AOG.0000000000001519>
- Su H, Li Z, Yuan T, Li H, and Wang (2024). Investigating the efficacy of anal dimple anorectoplasty in congenital anal atresia: A systematic review and meta-analysis. *Alternative Therapies in Health Medicine*, 2024: AT10521. Available at: <https://pubmed.ncbi.nlm.nih.gov/38940776/>
- Teixeira UR and de Araujo KC (2022). Anal atresia in cattle: A case report. *Revista Ibero-Americana de Humanidades*, 8(10): 1379-1390. DOI: <https://www.doi.org/10.51891/rea.v8i10.7242>
- Xiong S, Wang J, Zhu W, Yang K, Ding G, Li X, and Eun DD (2020). Onlay repair technique for the management of ureteral strictures: A comprehensive review. *BioMed Research International*, 2020(1): 6178286. DOI: <https://www.doi.org/10.1155/2020/6178286>
- Yarmuch J, Mayanz S, and Romero C (2015). Severe sepsis and surgery. *Revista Chilena de Cirugía*, 67(1): 79-87. DOI: <http://www.doi.org/10.4067/S0718-40262015000100014>

**Publisher's note:** Scieline Publication Ltd. remains neutral with regard to jurisdictional claims in published maps and institutional affiliations.



**Open Access:** This article is licensed under a Creative Commons Attribution 4.0 International License, which permits use, sharing, adaptation, distribution and reproduction in any medium or format, as long as you give appropriate credit to the original author(s) and the source, provide a link to the Creative Commons licence, and indicate if changes were made. The images or other third party material in this article are included in the article's Creative Commons licence, unless indicated otherwise in a credit line to the material. If material is not included in the article's Creative Commons licence and your intended use is not permitted by statutory regulation or exceeds the permitted use, you will need to obtain permission directly from the copyright holder. To view a copy of this licence, visit <https://creativecommons.org/licenses/by/4.0/>.